

허용 용량의 옥시코돈 투약 후 발생한 독성 뇌병증

건국대학교 의과대학 신경과학교실

정일억 · 송승훈 · 오지영

Toxic Encephalopathy at a Therapeutic Dose of Oxycodone

Ileok Jung, MD, Seung-Hoon Song, MD, Jeeyoung Oh, MD, PhD

Department of Neurology, Konkuk University School of Medicine, Seoul, Korea

ABSTRACT

A 39-year-old woman was referred to our department due to uncontrolled neuropathic pain. Her pain was slowly improved with combination of multiple drugs, including oxycodone, amitriptyline and gabapentin. During the treatment, she presented inappropriate speech, confusion, and amnesia. Findings of brain MRI and MR spectroscopy were compatible for opioid induced leukoencephalopathy. We discontinued oxycodone and administered intravenous naloxone, which gradually improved her encephalopathic symptoms. Our case indicated that toxic encephalopathy could occur even at the therapeutic dose of oxycodone.

(J Pain Auton Disord 2013;2:95-98)

KEYWORDS

Oxycodone, Encephalopathy, Naloxone

Oxycodone, a semisynthetic opioid, is the main active ingredient in a number of oral medications commonly prescribed for the relief of moderate and severe pain.

A toxic leukoencephalopathy resulting from heroin and methadone intoxication has been described in a few case reports since the early 1980s.¹⁻⁶ While the post-opioid toxic encephalopathy of these cases was mostly associated with massive dosages such as seen in accidental or illegal use (ingestion, inhalation or injection) of opioids,^{1,3-6} the relationship between therapeutic doses of oxycodone and toxic encephalopathy has not been documented. We recently encountered a patient with neuropathic pain who showed toxic encephalopathy with a therapeutic dose of oxycodone and who was successfully treated with naloxone.

CASE REPORT

A 39-year-old woman, hospitalized for compartment syndrome resulting from rhabdomyolysis of the right leg, was referred to our department due to uncontrolled neuropathic pain. She had no history of substance abuse and had no significant past history. During hospitalization for rhabdomyolysis, no medical complications such as liver and renal disease were observed. She had no neurological or psychological problems except for entrapment syndrome of the right leg. Per family reports and retrospective personal recall, she did not show any abnormal behavior at all during the initial hospitalization. The patient had been given intravenous morphine (pethidine 25 mg per day, tramadol 25 mg per day) for 2 weeks fol-

Received: October 10, 2013 / Revised: October 17, 2013 / Accepted: October 17, 2013

Address for correspondence: Jeeyoung Oh, MD, PhD
Department of Neurology, Konkuk University School of Medicine, 120-1 Neungdong-ro, Kwangjin-gu, Seoul 143-729, Korea
Tel: +82-2-2030-7564, Fax: +82-2-2030-5169, E-mail: serein@kuh.ac.kr

lowed by oral oxycodone tablets (40 mg per day from the initial dosage) for 3 weeks. Her pain slowly improved with the combination of multiple drugs that included amitriptyline (starting dose from 5 mg tid to 20 mg tid) and gabapentin (started from 100 mg tid to 800 mg three times per day) for another 4 weeks. While receiving doses of up to 70 mg amitriptyline per day, she presented with aggressive behavior, urinary incontinence and inappropriate speech. Since the anti-cholinergic effects of tricyclic antidepressants can cause psychiatric symptoms like confabulation, irritability due to tricyclic antidepressants was suspected at first, and the drug was discontinued immediately. Her symptoms, however, relentlessly deteriorated rather than improved.

On neurological examination, the patient showed alert mental status but disorientation to time and place. Cranial function test was normal and her right leg weakness with sensory deficit representing multiple neuropathies (sciatic, femoral nerve) showed no worsening. Neuropsychological examination including MMSE revealed diffuse higher cortical dysfunction, particularly of the frontal lobe and parietal lobe (Table 1, Fig 1-A). With regard to frontal lobe and executive functions, motor and cognitive inhibitory control ability and mental flexibility were markedly decreased. Constructional apraxia was significant and Gerstmann's syndrome including left-right disorientation and acalculia were observed. On memory examination, verbal and visual memory function was significantly impaired. Confabulation, impaired impulse control and depressive mood were also observed.

Electroencephalography showed generalized theta to delta activities reflecting diffuse cerebral dysfunction. Laboratory studies were

normal including creatine kinase, lactate dehydrogenase, ammonia, blood urine nitrogen, creatinine, electrolytes, liver enzymes, and thyroid hormones. Brain MRI showed symmetric diffusion restricted, confluent T2-hyperintensities in bilateral white matter (Fig. 1-C). Imaging findings brought into differential diagnosis of toxic or metabolic encephalopathy. On MR spectroscopy, an increased choline/creatine ratio with decreased NAA was noted, which was compatible with opioid induced leukoencephalopathy (Fig. 1-D). We discontinued oxycodone and administered intravenous naloxone as an antidote to the opioid for 2 weeks. Her neurological symptoms gradually improved with the treatment, and a month later, the follow-up MRI showed marked reduction in the volume of the lesion (Fig. 1-E). On follow-up neuropsychological evaluation 2 months later, she showed marked improvement in execution function including Luria loop test compared to the previous test (Table 1, Fig. 1-B). Decline of attention control, inhibitory control ability and mental flexibility was still observed, but verbal memory including other domain functions was within the normal range.

DISCUSSION

Opioid-induced toxic encephalopathy has been described in previously reported cases, most of which were related to accidental overdose or drug addiction.^{1,3-6} It seems that toxicity with any form and method of intake of high dose opiates can lead to leukoencephalopathy.

The analgesic efficacy of opioids does not have a conventional dose-related ceiling (opioid ph), but in a study on its efficacy in

Table 1. Serial results of neuropsychological test

Domain	2011/08/12	2011/10/26
MMSE	23/30	30/30
Digit span	Forward 6, backward 2	Forward 6, backward 4
K-BNT	49/60 (25 %ile)	53/60 (59 %ile)
Finger naming	Borderline	Normal
Memory Quotient	58	93
Fist-edge-palm test	Abnormal (perseveration)	Normal
Frontal assessment battery	11/18	17/18

MMSE, minimal status examination; K-BNT; Korean-Boston naming test.

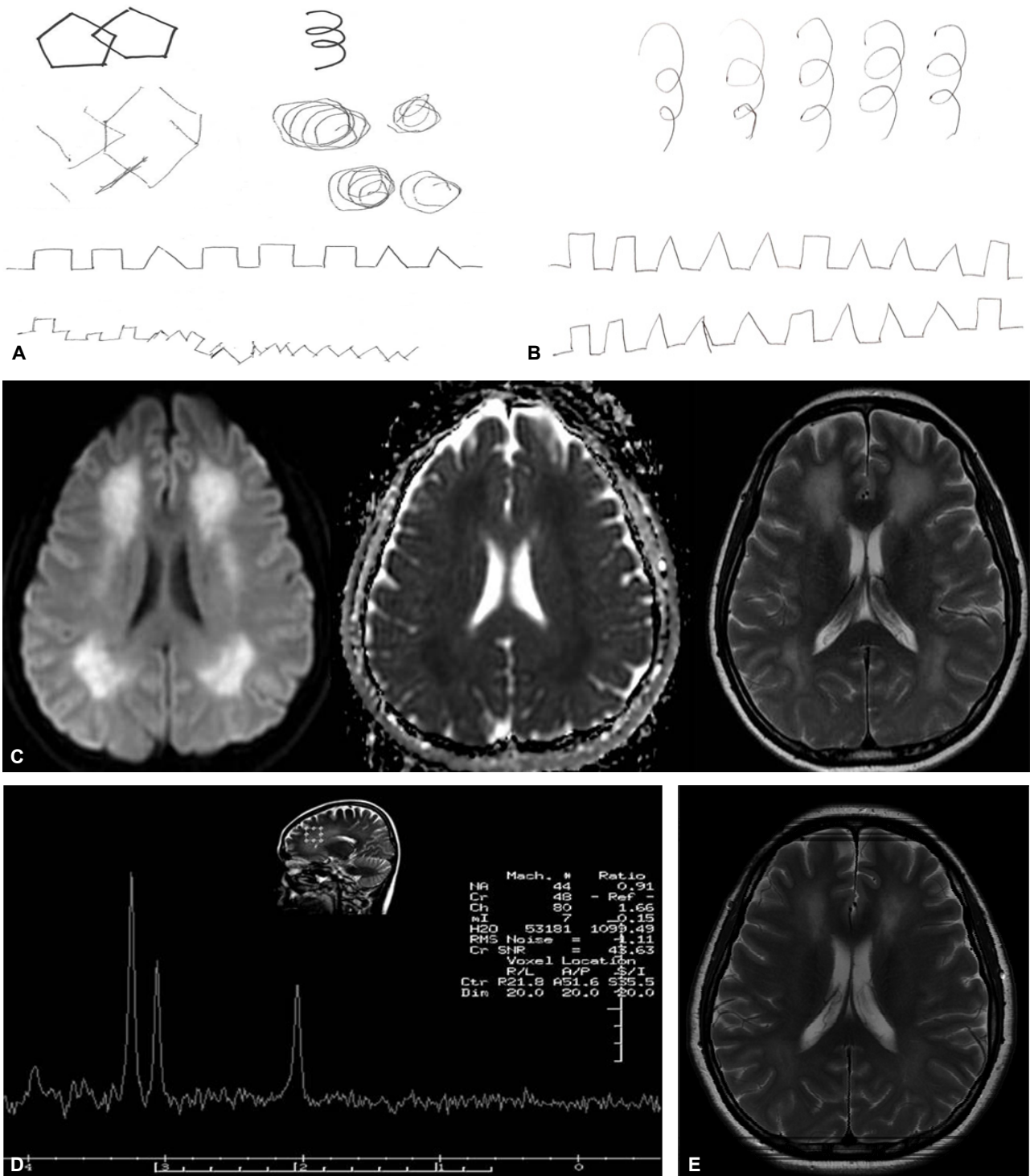


Figure 1. Severely impaired copies of an interlocking pentagon, Luria loop and alternating square and triangle, which showed visuospatial dysfunction and perseveration (A). Initial brain MRI revealed confluent hyperintensity in the bilateral white matter (C). MR spectroscopy showed an increased choline/creatine ratio and slightly decreased NAA, which was compatible with opioid induced leukoencephalopathy (D). A month follow up MRI showed decreased lesion extent with residual hyperintensity on T2-weighted MRI (E). She carried out copies of Luria loop and alternating square and triangle successfully 2 months later (B).

chronic non-cancer pain, the mean dose of oxycodone was 40 mg/day when the mean global pain intensity of the double blind treatment was significantly lower than that observed with the placebo.⁷ Therefore it is safe to assume that the amount of oxycodone used in our patient was within the therapeutic dose. To our knowledge, this is the first report of opioid related encephalopathy with a therapeutic dose.

A number of cases of previous reports that were associated with opioids mentioned confluent high-signal-intensity changes in the cerebral white matter on T2-weighted and FLAIR images, as were observed in our patient, with sparing of the subcortical U-fibers.⁵ In our case, a vascular event from an acute or subacute state was suspected since her neurologic deterioration, such as abnormal behavior, cognition decline and urinary symptoms, developed suddenly and worsened stepwise. Considering the absence of conventional vascular risk factors in her history and the diffuse restricted lesion in bilateral watershed areas on the diffusion weighted MR, vasoconstriction of the vascular smooth muscle by the opioid derivatives is a possible cause of the cerebral ischemia. The suggested mechanism for acute ischemia in the setting of opioid and morphine derivatives is thought to be reversible vasospasm, vasculitis or embolic events. Vasospasm may be attributed to the vasoconstrictor effects of the mu-opioid receptor on the vascular smooth muscle. Some studies have demonstrated that, in general, opioid abusers have an increase in T2 white matter hyperintensities as compared with healthy subjects, which has been attributed to the vasoconstrictor effects of opioids.³

Several other factors causing encephalopathy in this patient could be rhabdomyolysis, other drugs and their metabolites including amitriptyline and gabapentin. Amitriptyline is a well-known drug for its anticholinergic adverse effect. But neuropsychologic symptoms and signs of our patient were deteriorated despite of dis-

continuation of amitriptyline. Gabapentin may cause a reversible encephalopathy clinically characterized by asterixis. Every reported case of gabapentin induced encephalopathy was accompanied by asterixis and this symptom resolved on discontinuation of the drug.⁸ Our patient, however, did not show apparent asterixis and her MR images were not compatible with gabapentin induced encephalopathy. However, the toxicity of oxycodone could be potentiated with combination of these medications including additional hazard effect or decreased metabolic rate.

In conclusion, our case indicated that toxic encephalopathy can occur even at therapeutic doses of oxycodone. The possibility of toxic encephalopathy should be taken into account when administering opioid analgesics regardless of the dosage.

REFERENCES

1. Anselmo M, Rainho AC, Vale MC, Estrada J, Valente R, Correia M, et al. Methadone intoxication in a child: toxic encephalopathy? *J Child Neurol* 2006;21:618-620.
2. Kim DW, Im HJ, Oh J. Selective injury of the globus pallidus and hippocampus in methamphetamine-induced encephalopathy. *Clin Neuroradiol* 2013;23:51-53.
3. Borne J, Riascos R, Cuellar H, Vargas D, Rojas R. Neuroimaging in drug and substance abuse part II: opioids and solvents. *Top Magn Reson Imaging* 2005;16:239-245.
4. Morales Odiá Y, Jinka M, Ziai WC. Severe leukoencephalopathy following acute oxycodone intoxication. *Neurocrit Care* 2010;13:93-97.
5. Salgado RA, Jorens PG, Baar I, Cras P, Hans G, Parizel PM. Methadone-induced toxic leukoencephalopathy: MR imaging and MR proton spectroscopy findings. *AJNR Am J Neuroradiol* 2009;31:565-566.
6. Zanin A, Masiero S, Severino MS, Calderone M, Brousseau KM, Harris SN. A delayed methadone encephalopathy: clinical and neuroradiological findings. *J Child Neurol* 2010;25:748-751.
7. Kalso E. Oxycodone. *J Pain Symptom Manage* 2005;29(5 Suppl):S47-56.
8. Sechi G, Murgia B, Sau G, Peddone L, Tiroto A, Barrocu M, et al. Asterixis and toxic encephalopathy induced by gabapentin. *Prog Neuropsychopharmacol Biol Psychiatry* 2004;28:195-199.